

# Neonatal spongiform myelinopathy after restricted application of hexachlorophane skin disinfectant

JM ANDERSON,\* F COCKBURN,† JO FORFAR,† RA HARKNESS,‡  
RW KELLY,§ AND B KILSHAW‡

*From the \*Department of Pathology, Royal Hospital for Sick Children, Edinburgh EH9 1LJ; the †Department of Child Life and Health, University of Edinburgh, EH9 1UW; the ‡Department of Paediatric Biochemistry, Royal Hospital for Sick Children, Edinburgh EH9 1LJ; and the §MRC Reproductive Biology Unit, Edinburgh EH1 2QW, UK*

**SUMMARY** At least four out of 97 low birth weight (<1750 g) newborn infants who had received only limited skin disinfection with 3% hexachlorophane (HCP) emulsion developed spongiform myelinopathy in association with detectable amounts of HCP in their brains. These four cases were found in a post-mortem survey of 20 out of the 27 infants who died. Another nine of these infants had detectable amounts of HCP in the brain but no myelinopathy. It is at present not possible to define a 'safe' level of exposure to 3% HCP emulsion for small preterm infants in the first 2 weeks of life.

Hexachlorophane (HCP) is now subject to prescribing control but is available for use under medical supervision and widely employed for antiseptics in hospitals. It has played an important part in reducing neonatal staphylococcal infection, which can be such a serious problem in maternity nurseries,<sup>1</sup> but there is evidence that it can cause spongiform myelinopathy. Almost all the reported cases have been in infants of low birth weight.<sup>2-4</sup> A 'safe' level of exposure for infants has not been established.<sup>5</sup>

For the two-year period 1973-4 we continued to use HCP in the care of newborn infants, reducing the extent of application. We report here, for this two-year period, the relationship between the HCP concentration in brain tissue and spongiform myelinopathy in small preterm infants who died.

## Patients and methods

Over the period of the survey there were 8709 live births. Among them were 97 infants of birth weight less than 1750 g who survived one day or more. Twenty-seven out of the 97 died and 20 of these were examined postmortem. All had had 3% HCP in detergent (pHisoMed, Winthrop Laboratories) routinely applied to the body once daily and to the

napkin area after napkin changes. After application the treated area had been rinsed with water.

Conventional histological methods were used to screen for myelinopathy. Samples from representative levels in the neuraxis were examined, including myelinated regions of the brain stem. Special stains for myelin were used in cases showing spongiform change.

The HCP content of brain tissue was determined by mass spectrometry after purification of extracts. A cerebral hemisphere sample was examined in each of the 20 infants and a portion of brain stem from five infants. Brain stored in formalin was used since HCP can be recovered from brain after years in formalin and HCP does not leach into the fixative.<sup>4</sup> Also Vaterlaus (personal communication), using sensitive quantitative methods, had found no evidence that formalin extracted hexachlorophane from brain in the rat. Half-gram quantities were homogenised in 5 ml 0.4 mol/l phosphate buffer pH 7.5, to which 25 ng HCP (Methylene-<sup>14</sup>C) had been added. The homogenate was then extracted twice with 2 vol redistilled benzene. The extract was reduced in volume to about 1 ml and acetylated with 0.2 ml pyridine-acetic anhydride (1:1 v/v) for 15 min at 65°C. The acetylation products were chromatographed on a silica gel column 40 × 4 mm. The hexachlorophane diacetate in the residues was

measured on a Varian 1400 gas chromatograph coupled through an all glass jet separator to a Dupont 490B mass spectrometer. The mass spectrometer was tuned to two ions, m/e 406 and 408, which are strong isotope peaks of m/e 404 owing to the six chlorine atoms in HCP. The base peak in the HCP spectrum on the above GS-MS combination was m/e 408. Peaks were measured when they occurred at the appropriate retention time and had the expected ratios to each other and to the total ion current. The amounts of HCP diacetate were estimated by comparison with standards.

Radioactivity in the residues analysed by GC-MS was measured by liquid scintillation counting. Percentage recovery was consistent in the three major batches of analyses, the means ( $\pm$  SEM) being  $66.7 \pm 4.8\%$  ( $n = 20$ ),  $66.8 \pm 3.7\%$  ( $n = 20$ ), and  $68.7 \pm 2.5\%$  ( $n = 12$ ). To check the sensitivity and

specificity of the method brain samples from six 'cot death' infants who had no recent exposure to topical HCP were analysed without added radioactive HCP. No HCP was detected in any of these samples.

## Results

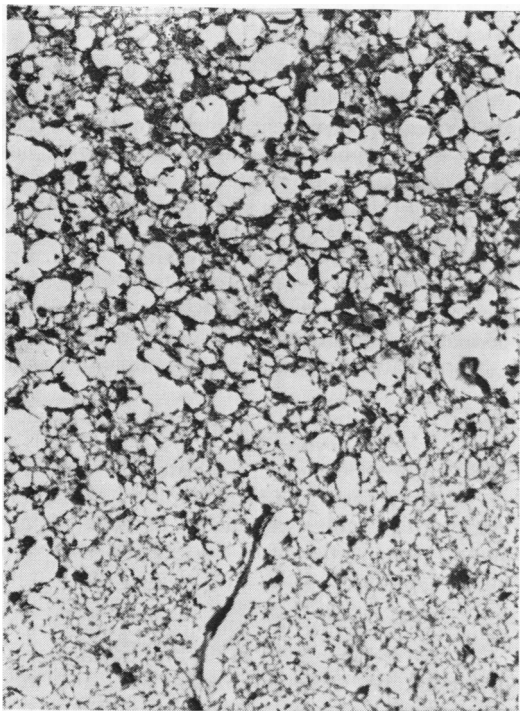
### HISTOLOGICAL FINDINGS

Spongiform myelinopathy of similar distribution, although varying in degree, was found in four out of the 20 infants examined (Table). Spongiform change was found throughout the myelinated regions, being particularly severe in medial structures of the medulla and the tegmental part of the pons. In contrast, white matter areas such as the corticospinal pathways, which are non-myelinated in preterm babies, were free of vacuolation (Figure). In paraffin sections vacuoles were mainly 10-30  $\mu\text{m}$  in transverse

### Clinical and pathological data in preterm infants examined postmortem for hexachlorophane in brain tissue

Case No.	Sex	Birth weight (g)	Gestation (weeks)	Birth asphyxia	RDS	Apnoeic attacks	Assisted ventilation	Convulsions	Coagulation defect	Blood transfusion	Age at death (days)	Necropsy weight (g)	Primary necropsy findings	HCP concentration in (a) cerebrum (b) brain stem (ng/g)
<i>Spongiform myelinopathy</i>														
1	F	907	29	-	+	-	-	-	-	-	50	1480	Systemic candidiasis with endocarditis and brain abscesses. Renal infarction Prematurity	(a) 41 (b) 0
2	M	1134	28	+	+	-	+	-	+	-	11	1075	Prematurity	(a) 186 (b) 101
3	M	1134	28	-	-	-	-	-	-	-	17	1140	Prematurity	(a) 281 (b) 181
4	F	1729	32	-	+	-	-	-	-	-	9	1420	iv haemorrhage. Meningitis ( <i>E. coli</i> )	(a) 6 (b) 0
<i>No spongiform myelinopathy: detectable hexachlorophane in brain</i>														
5	F	902	30	+	+	-	-	-	-	-	2	892	iv haemorrhage. Prematurity	(a) 20
6	M	1276	28	-	+	-	-	-	-	-	1	1325	Prematurity	(a) 18
7	M	1030	29	-	-	-	-	-	-	-	4	1032	Subdural haemorrhage	(a) 40
8	M	1134	28	-	-	-	-	-	-	-	5	1077	iv haemorrhage. Intracerebral haemorrhage.	(a) 10
9	M	912	28	+	+	-	+	-	+	+	1	912	Bronchopneumonia iv haemorrhage. Pneumonia. Hydronephrosis	(a) 16
10	M	1020	27	-	+	-	-	-	-	+	37	910	Septicaemia	(a) 20
11	F	1503	30	-	+	-	-	-	+	-	5	1285	iv haemorrhage	(a) 3*
12	M	1162	25	-	-	-	+	+	+	+	11	1327	Septicaemia. Meningitis ( <i>E. coli</i> )	(a) 8
13	M	1134	25	-	+	-	+	-	-	+	2	1090	Subdural haemorrhage. Pulmonary haemorrhage	(a) 3*
<i>No spongiform myelinopathy: no detectable hexachlorophane in brain</i>														
14	F	775	27	-	+	-	-	-	+	-	3	775	iv haemorrhage. Kernicterus	No detectable HCP
15	M	1162	31	-	+	-	+	-	-	-	2	1097	iv haemorrhage	" " "
16	M	1134	28	-	+	-	-	-	-	-	1	1110	iv haemorrhage	" " "
17	F	1021	27	+	+	-	-	-	-	-	4	1040	iv haemorrhage. Cerebral infarction. Pneumothorax	" " "
18	M	1389	33	-	+	-	-	-	-	-	1	1325	iv haemorrhage	" " "
19	F	1021	35	-	+	-	-	-	-	-	1	1019	Prematurity	" " "
20	F	992	30	-	-	-	-	-	-	-	1	940	iv haemorrhage	" " "

\*The internal standard of  $^{14}\text{C}$  HCP contributed a mean 'blank' of 34 ng/g with a range of  $\pm$  3 SEM of 28-37 ng which has been subtracted from all data. The asterisk values would be zero if the upper value is used. The molecular weight of hexachlorophane is 407. iv = intraventricular.



Case 3: medulla. Myelinated medial longitudinal fasciculus shows vacuolation; non-myelinated corticospinal pathway free of spongy change. Luxol fast blue/cresyl violet  $\times 200$ .

diameter and up to 100  $\mu\text{m}$  longitudinally. Stains for myelin showed myelin membranes outlining many vacuoles. There was no sign of glial or phagocytic reaction to the myelinopathy. Two of the infants with spongiform change also had inflammatory lesions of the central nervous system. In one, multiple brain abscesses (*Candida* sp) were present and in another, suppurative meningitis (*Escherichia coli*).

#### HCP CONCENTRATIONS

Brain tissue from all of the infants with myelinopathy contained HCP. Large quantities up to 280 ng/g wet weight were present in two and much smaller amounts in the two others (Table). More was recovered from cerebral tissue than from brain stem. There was a correlation between the concentration of HCP in the brain and the degree of myelinopathy. The two infants with high concentrations of HCP (281 and 186 ng/g) both had well developed myelinopathy at 17 and 11 days of age, another infant (41 ng/g) had moderate myelinopathy at 7 weeks, while the fourth (6 ng/g) had only a minor degree of spongiform change at 9 days.

Nine other infants had measurable amounts of HCP in brain tissue (3-40 ng/g) but no histological abnormalities. Their ages at death ranged from 1 to 37 days. Six suffered from intracranial bleeding and four showed evidence of infection.

Seven other infants had no spongiform myelinopathy and no, or unmeasurable, traces of HCP in brain tissue. The ages of these infants ranged from 1 to 4 days. Six of them had suffered from intraventricular haemorrhage.

#### CLINICAL CORRELATIONS

Essential clinical features are shown in the Table. Apart from low birth weight, the respiratory distress syndrome, apnoea requiring assisted ventilation, and coagulation defects were common features. These are common features in low birth weight preterm infants who die in the neonatal period, and in respect of them there was no significant difference between infants with or without spongiform myelinopathy or between infants with or without HCP in brain tissue. Only one of the four infants with spongiform myelinopathy had evidence of asphyxia at birth: two convulsed, but one of those did so within a few hours of delivery in association with the early development of apnoeic attacks. Among the preterm infants examined there was no notable difference in gestational age between the three major groups (Table) defined by the presence of hexachlorophane or myelinopathy, or both.

The main distinction between the three groups was in the length of survival. In cases of spongiform myelinopathy the average length of survival was 22 days, in cases without spongiform myelinopathy but with detectable HCP in brain tissue 7.5 days, and in cases without myelinopathy or detectable HCP in brain two days. Statistical analysis by fitting a linear regression after logarithmic transformation of the data showed that the older mean age for the group with spongiform myelinopathy was significantly different ( $0.01 > P < 0.001$ ) from the group without such change. The highest concentrations of HCP in brain tissue, 281 and 186 ng/g, were seen in infants who survived 17 and 11 days respectively. The HCP concentration in the longest survivor (50 days) (who had spongiform myelinopathy) was 41 ng/g. The second longest survivor (37 days) (who had no spongiform myelinopathy) had a HCP brain tissue concentration of 20 ng/g.

While absent or negligible concentrations of HCP in brain were found only in infants whose treatment had not extended beyond five days, significant brain concentrations were found in seven infants who had been treated for up to this length of time only. The numbers of boys and girls in the group with spongiform myelinopathy and in the group without such

change who show no HCP were about equal, but there were seven boys and only two girls in the group with no spongioform myelinopathy but with detectable HCP in brain. Three of the four infants with spongioform myelinopathy had associated hyperbilirubinaemia (247, 208, and 185  $\mu\text{mol/l}$ ), but four of the nine with no spongioform myelinopathy and detectable brain tissue concentrations also suffered from hyperbilirubinaemia. Among the six infants surviving for more than one week the three with the lowest brain HCP concentrations had received at least one dose of dexamethasone or hydrocortisone.

## Discussion

This survey confirms that small preterm infants weighing less than 1.75 kg may develop spongioform myelinopathy from about 1 week of age onwards in association with the application of 3% HCP emulsion and have significant amounts of HCP in their brain tissue. Four out of six infants who survived for a week or more had spongy change, a similar incidence to that reported by Powell *et al.*<sup>2</sup> and Shuman *et al.*<sup>3</sup> in small preterm infants surviving for similar lengths of time. Gowdy and Ulsamer also detected hexachlorophane in association with spongioform myelinopathy in five out of the 11 preterm infants they examined.<sup>6</sup> They found somewhat higher concentrations of HCP than ours, probably owing to their use of a less specific method of detection.<sup>4</sup>

In monkeys given HCP 5 mg/kg daily by subcutaneous injection for a month myelinopathy is associated with brain concentrations of HCP of 180-490 ng/g.<sup>7</sup> There are various causes of neonatal spongioform myelinopathy such as some inborn errors of amino-acid metabolism,<sup>8</sup> but in the two infants with brain concentrations of HCP of 281 and 186 ng/g HCP seems likely to have played some part in its development. No firm conclusion can be reached about the two infants who showed only a minor degree of spongy change and no higher concentrations of HCP in brain than infants showing no myelinopathy. It is still possible, however, that HCP contributed to the development of their myelinopathy since HCP is cleared from tissues very much more rapidly than myelinopathy resolves.<sup>7</sup> The difficulties in interpreting the histological appearances is highlighted by one report<sup>6</sup> in which two infants showed brain vacuolation but had not been exposed to HCP.

That significant concentrations of HCP occur in brain tissue even after one day of treatment indicates how rapidly HCP is absorbed through the skin of a small preterm infant. The relatively lower concentrations seen after one month may indicate diminished absorption through the skin at this time asso-

ciated with more effective tissue clearance.

As in previous studies, no distinctive clinical features of neonatal HCP intoxication were evident. Neither was there clinical evidence that HCP myelinopathy leaves permanent damage in the nervous system.<sup>9,10</sup> Experimentally, spongioform change has been shown to resolve in 6-12 weeks after withdrawing HCP<sup>11</sup> but it is not known whether there is a lasting deficit of myelin. By analogy with the effect of under-nutrition on the growing brain,<sup>12</sup> interruption of the process of myelination at a time when this is proceeding rapidly might be expected to result in permanent myelin loss. One experimental study has shown that axonal damage, incapable of repair, may occur.<sup>13</sup>

Despite the absence of clinical neurological abnormalities the evidence of absorption and of possible pathological effect indicates the need for great caution in the use of HCP emulsion on the skin of newborn infants, especially abraded skin.<sup>14</sup> Seemingly it is in the early days of life, probably during the first two weeks, that a small preterm infant is most vulnerable, especially when jaundiced. This may be related to the character of the skin at this time and to immaturity of the hepatic glucuronyl transferases and excretion mechanisms. It would therefore appear unwise to use 3% HCP emulsion on the skin of infants weighing under 1750 g during the first two weeks of life at least. The evidence does not seem to justify a total ban on the use of HCP, particularly in view of its undoubted value in preventing neonatal staphylococcal infection, which has recently been confirmed by a 'controlled' trial in the population we have studied (Tonkin, personal communication). There is need for further information on the possibly less toxic effects of HCP in dusting powder, another common form of topical application.

## References

- Forfar JO, Gould JC, Maccabe AF. Effect of hexachlorophane on incidence of staphylococcal and gram negative infection in newborn. *Lancet* 1968;ii:177-80.
- Powell H, Swarner O, Gluck L, Lampert P. Hexachlorophane myelinopathy in premature infants. *J Pediatr* 1973; 82:976-81.
- Shuman RM, Leech RW, Alvord EC. Neurotoxicity of hexachlorophane in humans. A clinicopathological study of 46 premature infants. *Arch Neurol (Chicago)* 1975;32: 320-5.
- Anderson JM, Kilshaw BH, Harkness RA, Kelly RW. Spongioform myelinopathy in premature infants. *Br Med J* 1975;ii:175.
- Anonymous. Hexachlorophane—yes or no? *Br Med J* 1977;i:337-8.
- Gowdy JM, Ulsamer AG. Hexachlorophane lesions in newborn infants. *Am J Dis Child* 1976;130:247-50.
- Kimbrough RD. Review of recent evidence of toxic effects

- of hexachlorophene. *Pediatrics* 1973;**51**:(Supplement) 391-4.
- <sup>8</sup> Anderson JM. Spongy degeneration in the white matter of the central nervous system in the newborn: pathological findings in three infants, one with hyperglycaemia. *J Neurol Neurosurg Psychiatry* 1969;**32**:328-37.
- <sup>9</sup> Plueckhahn VD, Collins RB. Hexachlorophene emulsions and antiseptic skin care of newborn infants. *Med J Aust* 1976;**1**:815-9.
- <sup>10</sup> Herskowitz J, Rosman NP. Acute hexachlorophene poisoning by mouth in a neonate. *J Pediatr* 1969;**94**:495-6.
- <sup>11</sup> Kimbrough RD, Gaines TB. Hexachlorophene effects on the rat brain. *Arch Environ Health* 1971;**23**:114-8.
- <sup>12</sup> Dobbing J. Vulnerable periods in developing brain. In: Davidson AN, Dobbing J, eds. *Applied Neurochemistry*. Oxford: Blackwell, 1968:287-316.
- <sup>13</sup> Lampert P, O'Brien J, Garrett M. Hexachlorophane encephalopathy. *Acta Neuropathol (Berl)* 1973;**23**:326-33.
- <sup>14</sup> Tyralla EE, Hillman LS, Hillman RE, Dodson WE. Clinical pharmacology of hexachlorophene in newborn infants. *J Pediatr* 1977;**91**:481-6.

Requests for reprints to: Dr JM Anderson, Department of Pathology, Ninewells Hospital, Dundee DD1 9SY.